

SUPPLEMENTARY MATERIAL

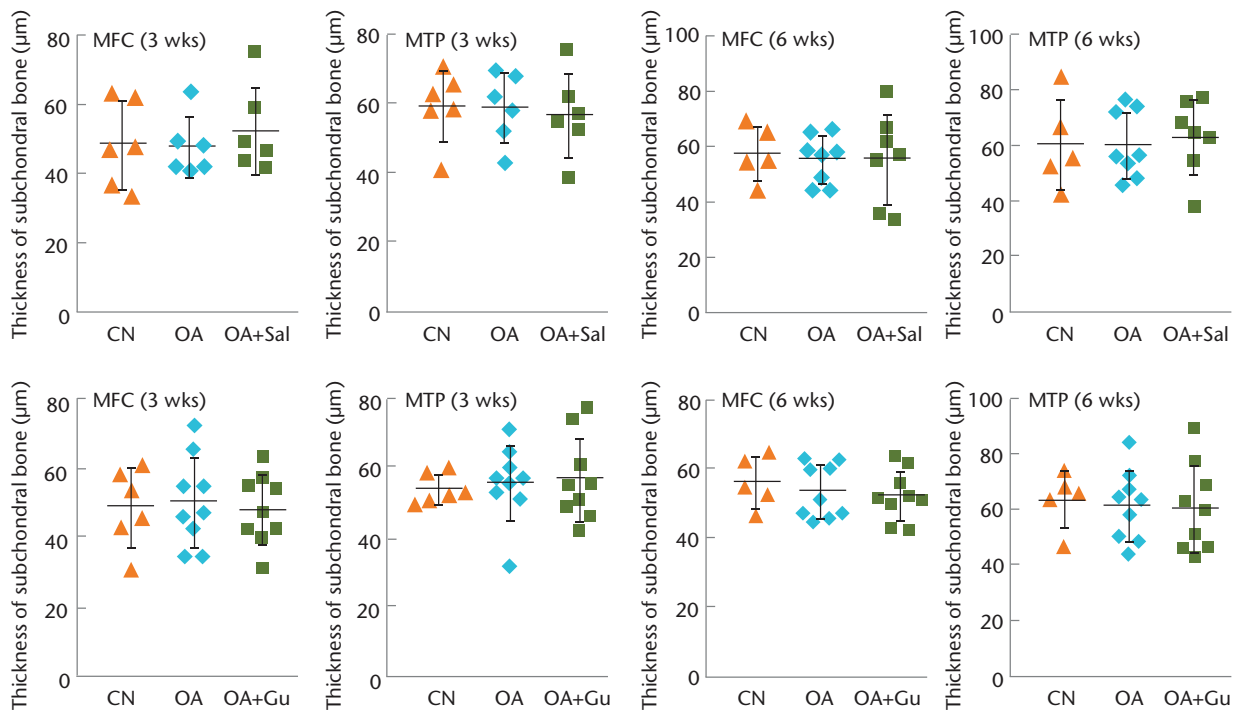


Fig. a

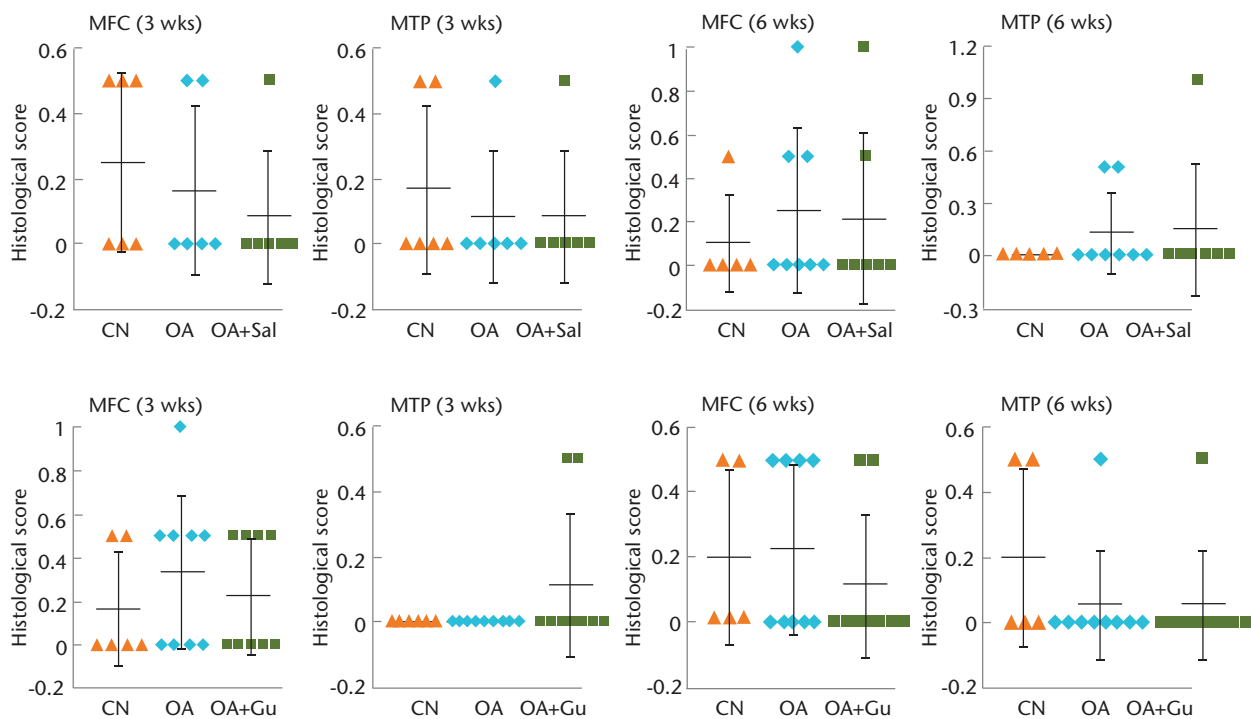


Fig. b

Graphs showing no significant effects of osteoarthritis induction and administration of Salubrin or Guanabenz on the contralateral knee, with a) thickness of subchondral bone of contralateral medial femoral condyle (MFC) and medial tibial plateau (MTP) in response to Salubrin or Guanabenz and b) histological score of contralateral MFC and MTP in response to Salubrin or Guanabenz shown.