

Hydroxyapatite ceramic-coated femoral components in younger patients followed up for 27 to 32 years

an update of a previous report

Correspondence should be sent to P. K. Upadhyay
Piyushupadhyay@hotmail.com

Cite this article:
Bone Jt Open 2024;5(4):
286–293.

DOI: 10.1302/2633-1462.
54.BJO-2023-0136.R1

P. K. Upadhyay,^{1,2} V. Kumar,⁴ S. B. Mirza,⁵ N. Shah,³

¹Cumberland Infirmary, North Cumbria Integrated Care NHS Foundation Trust, Carlisle, UK

²School of Engineering University of Warwick, Coventry, UK

³University Hospitals Sussex NHS Foundation Trust, West Sussex, UK

⁴Manchester University NHS Foundation Trust (MFT), Manchester, UK

⁵Trauma and Orthopaedics, University Hospital Wales, Cardiff, UK

Aims

This study reports the results of 38 total hip arthroplasties (THAs) in 33 patients aged less than 50 years, using the JRI Furlong hydroxyapatite ceramic (HAC)-coated femoral component.

Methods

We describe the survival, radiological, and functional outcomes of 33 patients (38 THAs) at a mean follow-up of 27 years (25 to 32) between 1988 and 2018.

Results

Of the surviving 30 patients (34 THAs), there were four periprosthetic fractures: one underwent femoral revision after 21 years, two had surgical fixation as the stem was deemed stable, and one was treated nonoperatively due to the patient's comorbidities. The periprosthetic fracture patients showed radiological evidence of change in bone stock around the femoral stem, which may have contributed to the fractures; this was reflected in change of the canal flare index at the proximal femur. Two patients (two hips) were lost to follow-up. Using aseptic loosening as the endpoint, 16 patients (18 hips; 48%) needed acetabular revision. None of the femoral components were revised for aseptic loosening, demonstrating 100% survival. The estimate of the cumulative proportion surviving for revisions due to any cause was 0.97 (standard error 0.03).

Conclusion

In young patients with high demands, the Furlong HAC-coated femoral component gives excellent long-term results.

Take home message

- In young patients with high demands, the Furlong hydroxyapatite ceramic-coated femoral component gives excellent long-term results.

Introduction

Cemented total hip arthroplasty (THA) gives excellent results in the elderly.¹ However, concerns have been raised about its longevity in younger patients. Demographic data from the National Joint Registry (NJR) of England, Wales, Northern

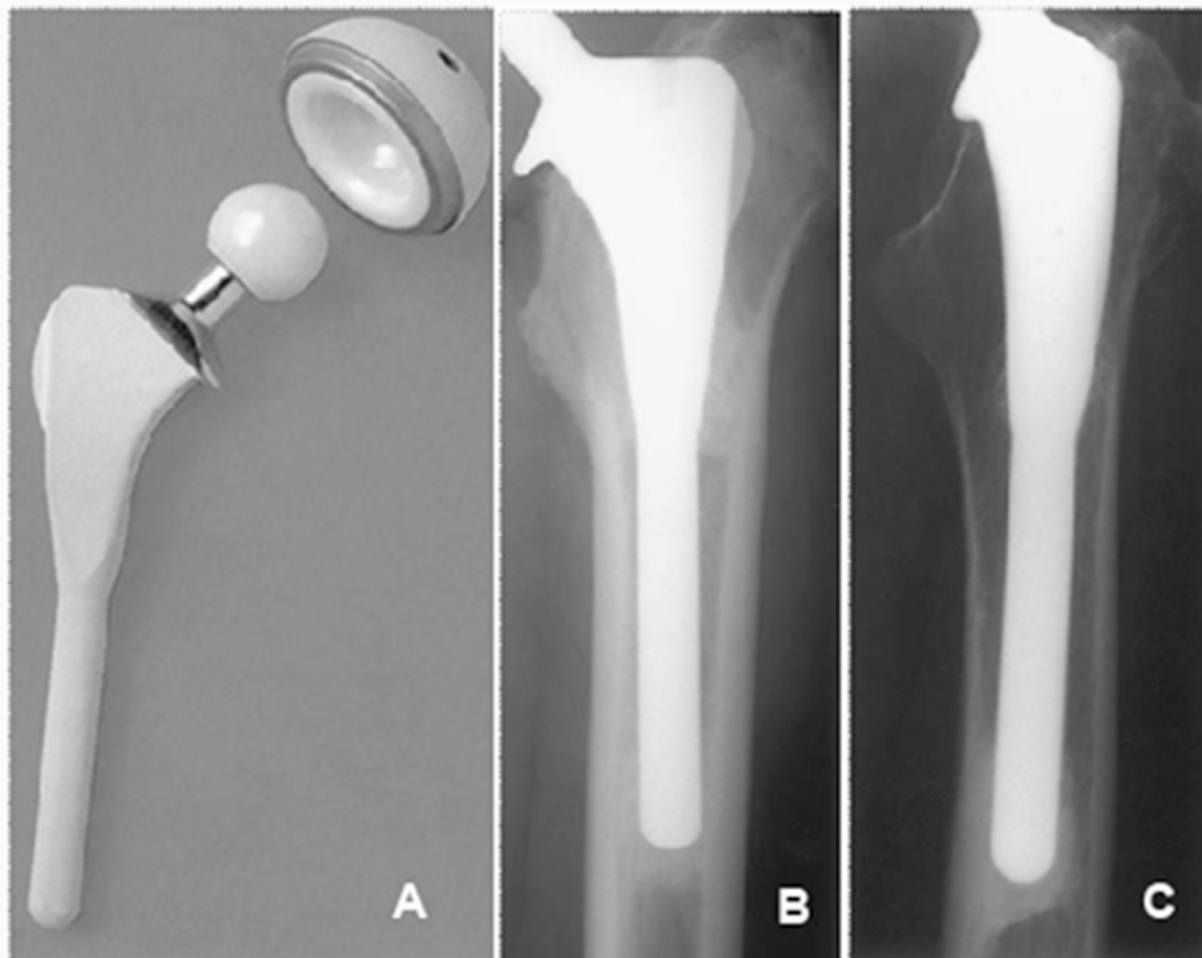


Fig. 1
Furlong stem and intergration.

Ireland, the Isle of Man and Guernsey demonstrate that in patients aged under 50 years, less than 5% of hip arthroplasties performed were cemented, reflecting surgical practice in this group.²

Cementless components depend on primary press-fit and secondary osseointegration to form a stable bond with the surrounding bone. The osseointegration may be improved by the use of hydroxyapatite ceramic (HAC) coating which, as well as stimulating osseointegration, creates a seal around the implant, providing resistance to the ingress of osteoclasts and subsequent osteolysis at the bone-implant interface.

The Furlong HAC-coated femoral stem prosthesis (Joint Replacement Instrumentation (JRI), UK), a collared modular implant made of titanium alloy, was used. The HAC coating has a crystallinity of 65% and a density of 85%. The implant is fully coated with more than 90% pure HA to a thickness of 150 μm by a plasma spray process performed in a vacuum (Figure 1).

We have reported the radiological and clinical outcomes of the Furlong femoral stem in young active patients at ten, 16, and 25 years postoperatively in 2004,³ 2009,⁴ and 2015,⁵ respectively. In this paper, we present the results of the same cohort at a mean of 27 years (25 to 32).

Methods

Between December 1988 and October 1997, 38 THAs were performed on 33 young patients by an experienced surgeon (JE) or under his direct supervision, using the Hardinge approach. All patients (22 males and 11 females) were aged less than 50 years, with a mean age of 42 years (22 to 49). Their mean height was 159 cm (140 to 180), and their mean weight was 76 kg (46 to 105). The mean BMI was 27 kg/m^2 (22 to 33), with eight patients classified as overweight with a BMI of > 30 kg/m^2 .

The indication for surgery was osteoarthritis in 19 hips (50%), developmental dysplasia of the hip (DDH) in ten (26%), post-traumatic arthritis in three (8%), Perthes' disease in two (5%), Still's disease in two (5%), rheumatoid arthritis in one (3%), and slipped upper femoral epiphysis in one (3%).

The Furlong HAC-coated femoral component was used in all patients. In the first 14 patients (14 hips; 37%), a cemented, monoblock ultra-high molecular weight polyethylene (UHMWPE) acetabular component was used (JRI). In the remaining 19 patients (24 hips, 63%), the JRI cancellous screw fit (CSF) acetabular component was used with a UHMWPE liner. The CSF acetabular component is a cementless, HAC-coated hemispherical shell, the fixation of which may be augmented using screws if required. Screws were used in ten hips; unused screw holes were filled with acetabular reamings.

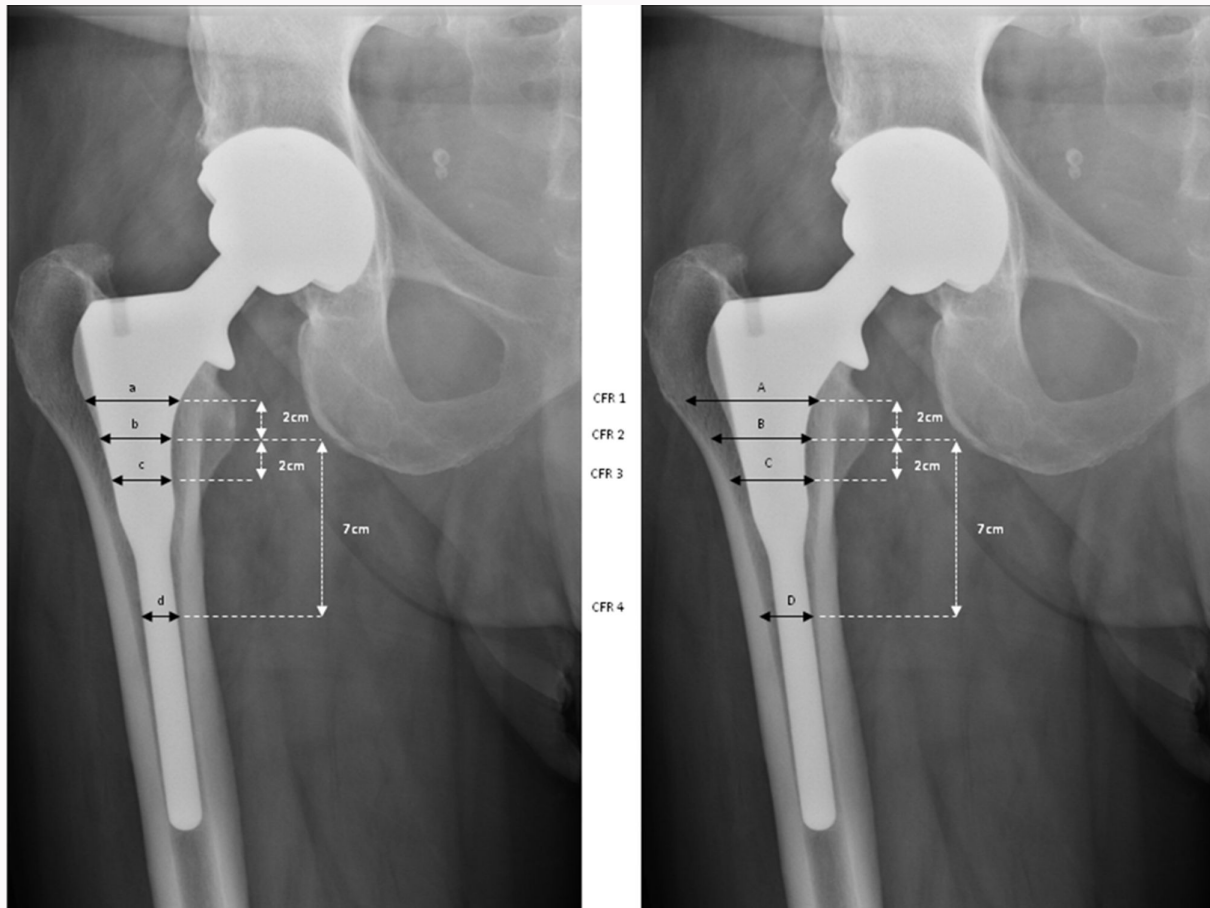


Fig. 2

Radiological measurements: canal flare index (CFI = A/D) and canal fill ratios (CFRs) at 2 cm above the lesser trochanter (CFR 1 = a/A), at the lesser trochanter (CFR 2 = b/B), 2 cm below the lesser trochanter (CFR 3 = c/C), and 7 cm below the lesser trochanter (CFR 4 = d/D).

The modular femoral head was alumina ceramic in 31 patients (36 hips, 95%) and cobalt chromium in two patients (two hips). Head diameter was either 28 mm (24 hips; 63%) or 32 mm (14 hips; 37%).

Prior to each of patient's visit, a letter was sent inviting them to the clinic for a follow-up appointment and informing them that functional data will be obtained. Formal informed consent was obtained from the patients when they arrived in clinic for use of their data in research. In addition, for this follow-up (mean 27 years), the current study was registered with the research and audit department (reference number 1491) and presented in the department's clinical governance meeting for discussion and quality assurance. The Harris Hip Score (HHS)⁶ was completed for all patients prior to surgery. At postoperative review (six months following surgery and then at a mean of ten, 16, 21, and finally at 27 years (27 to 32)), the HHS, the Oxford hip score (OHS),^{7,8} University of California Los Angeles (UCLA) activity scale,⁹ and patient satisfaction were recorded.

At the final review, radiological assessment was carried out by two independent observers (PKU, NS). The Dorr classification¹⁰ of all femora was established based on preoperative radiographs. Anteroposterior (AP) radiographs were assessed for stability of the femoral component using Engh et al's¹¹ criteria. The component was considered stable if there was evidence of osseointegration, and deemed unstable

if there was evidence of migration. Any radiolucencies with cystic or scalloped appearances were indicative of osteolysis, which was categorized using the seven zones described by Gruen et al,¹² using Goetz et al's¹³ criteria.

Acetabular radiolucencies were categorized using the DeLee and Charnley zones.¹⁴ Progressive radiolucencies around the acetabular component or any change in its position were taken to indicate loosening. Heterotopic ossification in the periarticular area was recorded using Brooker et al's¹⁵ criteria.

Femoral morphology and femoral component filling were calculated by the canal fill ratio (CFR) at the level of the lesser trochanter, 2 cm above, and 2 and 7 cm below (Figure 2); this was performed by dividing the width of the femoral component with the intramedullary bone canal. The canal flare index (CFI) was determined by measuring the ratio of the diameter of the femoral canal at the isthmus in the AP view to the diameter of the canal 7 cm below the lesser trochanter (Figure 2). These parameters were collected at the 17- to 25-year follow-up and current follow-up.

Statistical analysis

Cumulative survival analysis using the Kaplan-Meier¹⁶ method was performed for the acetabular and femoral components using revision or impending revision as an endpoint for all

Table I. Results of radiological measurements.

Variable	Data	p-value
Dorr type, n (%)		
A	17 (44.7)	N/A
B	20 (52.6)	N/A
C	1 (2.6)	N/A
Median canal fill ratio (95% CI)		
2 cm above LT (17- to 25-yr follow-up)	0.8 (0.8 to 0.9)	0.795
2 cm above LT (25- to 32-yr follow-up)	0.8 (0.8 to 0.9)	N/A
At LT (17- to 25-yr follow-up)	0.6 (0.6 to 0.7)	0.648
At LT (25- to 32-yr follow-up)	0.6 (0.6 to 0.8)	N/A
Below LT (17- to 25-yr follow-up)	0.6 (0.6 to 0.7)	0.478
2 cm below LT (25- to 32-yr follow-up)	0.5 (0.5 to 0.6)	N/A
7 cm below LT (17- to 25-yr follow-up)	0.7 (0.7 to 0.8)	0.488
7 cm below LT (25- to 32-yr follow-up)	0.7 (0.7 to 0.8)	N/A
Median canal flare index (95% CI)	2.9 (2.9 to 3.3)	N/A

CI, confidence interval; LT, lesser trochanter ; N/A, not applicable; N/S, not significant.

Table II. Bone morphology in periprosthetic fractures.

Variable	Patient 1	Patient 2	Patient 3	Patient 4
Dorr type	B	B	B	A
Canal fill ratio, n				
2 cm above LT (17- to 25-yr follow-up)	0.4	0.7	0.9	0.8
2 cm above LT (25- to 32-yr follow-up)	0.4	0.6	0.8	0.8
At LT (17- to 25-yr follow-up)	0.4	0.6	0.6	0.6
At LT (25- to 32-yr follow-up)	0.4	0.6	0.6	0.6
2 cm below LT (17- to 25-yr follow-up)	0.6	0.7	0.6	0.7
2 cm below LT (25- to 32-yr follow-up)	0.5	0.6	0.4	0.6
7 cm below LT (17- to 25-yr follow-up)	0.6	0.8	0.8	0.7
7 cm below LT (25- to 32-yr follow-up)	0.5	0.8	0.5	0.6
Canal flare index	2.7	3.3	2.8	3.6

LT, lesser trochanter.

causes. Survival analysis for aseptic loosening as a cause of revision was also calculated.

The level of agreement was then determined using intraclass correlation coefficients (ICCs)¹⁷ for continuous data and Gwet's AC¹⁸ for categorical data results can be interpreted as < 0.40 (poor); 0.40 to 0.59 (fair); 0.60 to 0.74 (good); and 0.75 to 1.00 (excellent). Interobserver repeatability was excellent (ICC 0.9 (95% confidence interval (CI) 0.83 to 0.97)) and for CFR ICC 0.97 (95% CI 0.94 to 0.97), and good for femoral Dorr type (Gwet's AC 0.72 (95% CI 0.5 to 0.9)).

The Shapiro-Wilk test was used to verify the normality of distributions. For non-normally distributed quantitative data, significance of differences among paired data was determined using the Wilcoxon signed-rank test, and for normally distributed data the paired *t*-test.

Results

At the time of this review, three patients (four hips) had died of unrelated causes. A total of seven patients (eight hips) had moved out of our area and were unable to attend our institution for clinical and radiological review. All were telephoned and OHS and satisfaction scores completed, they were asked to attend their local orthopaedic unit for radiographs. Two patients were lost to follow-up as they had left UK. Two patients declined to attend the clinic for outcomes score, but were happy with their hip arthroplasty; these were included in survival analysis.

Radiographs were assessed for Dorr stem type: 17 hips (45%) were Dorr A, 20 hips (53%) were Dorr B, and one hip (2%) was Dorr C. The CFI and CFR results are presented in Table I, and did not show any statistically significant change over the period the patients were followed up. The femur morphology of the periprosthetic fractures was analyzed, and are presented in Table I and Table II.

All femoral components available for review were stable with no radiological evidence of subsidence. Proximal

femoral radiolucencies (Gruen zones 1 and 7) were seen in seven hips; these lines were non-progressive with good osseointegration in the remainder of the metaphysis and trabecular remodelling. Another patient (one hip) with similar changes had rheumatoid arthritis, but remained asymptomatic.

Two patients had progressive acetabular radiolucencies; two were asymptomatic and with radiolucencies in DeLee and Charnley zones (zone 2 and zone 3, respectively). Heterotopic ossification was seen in 22 patients (24 hips, 63%), and was Brooker grade¹⁵ I in 14 hips, grade II in four, and grade III in six. This remained stable since the last report.⁵

The mean preoperative HHS was 44 (18 to 72), improving to 92 (43 to 99) at ten years, before falling to 89 (43 to 99) at 16 years, 79 (34 to 98) at 25 years, and 86 (49 to 100) at the latest follow-up. The mean OHS was 44 (8 to 48) at ten years, 42 (10 to 48) at 16 years, 39 (9 to 48) at 25 years, and 40 (8 to 48) at the latest follow-up. The mean UCLA score was introduced at the 16-year follow-up, at which time it was 6 (6 to 9), at 25 years it was 5 (2 to 9), and 6.5 (3 to 10) at the latest follow-up. A total of 18 patients (21 hips) rated their hips as excellent, two as very good, three as good, two as fair, and one patient, who was awaiting acetabular revision, rated their hip as poor.

There were four (10.5%) periprosthetic fractures postoperatively (Figure 3), and one femoral component had been revised following a periprosthetic fracture at 21 years in a patient who had previously been asymptomatic. Two patients had falls resulting in periprosthetic fractures; as the femoral component was deemed stable intraoperatively, the fracture was treated by internal fixation with a good outcome. One patient had their periprosthetic fracture treated nonoperatively as she used a wheelchair due to her medical comorbidities. One patient, who presented with a dislocation 12 years postoperatively, underwent a closed reduction, and no further dislocations were reported. No other complications, including

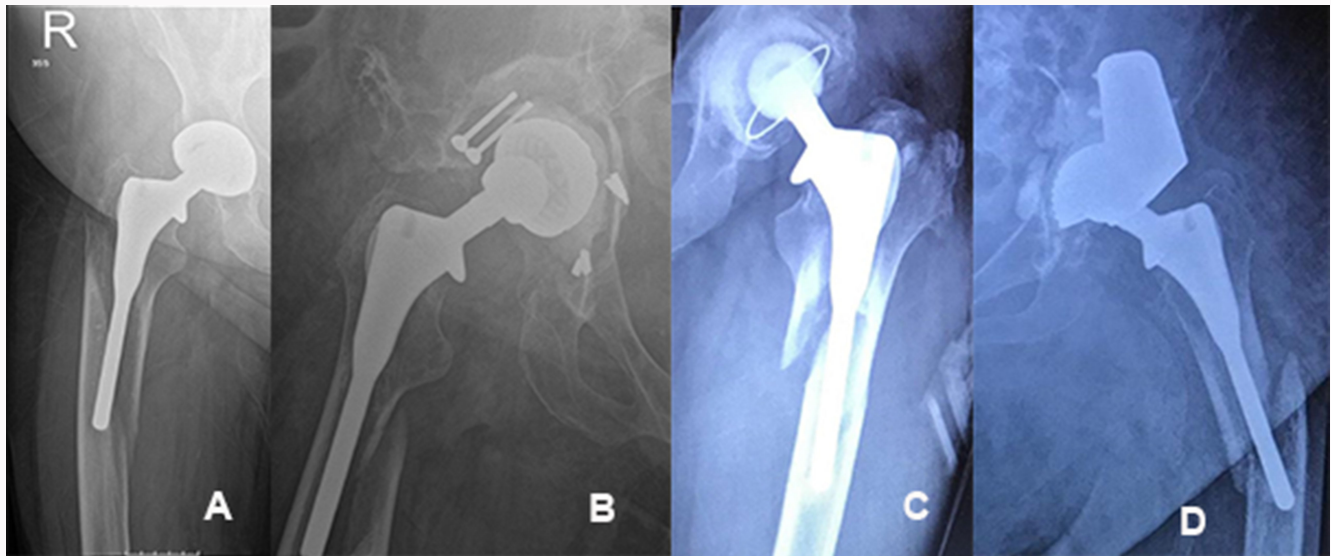


Fig. 3

Radiographs of patients with periprosthetic fractures. a) 60-year-old female, who was aged 51 years when the fracture occurred. b) 76-year old female, who was aged 66 years when the fracture occurred. c) 72-year old male, who was aged 67 years when the fracture occurred. d) 67-year-old male, who was aged 62 years when the fracture occurred.

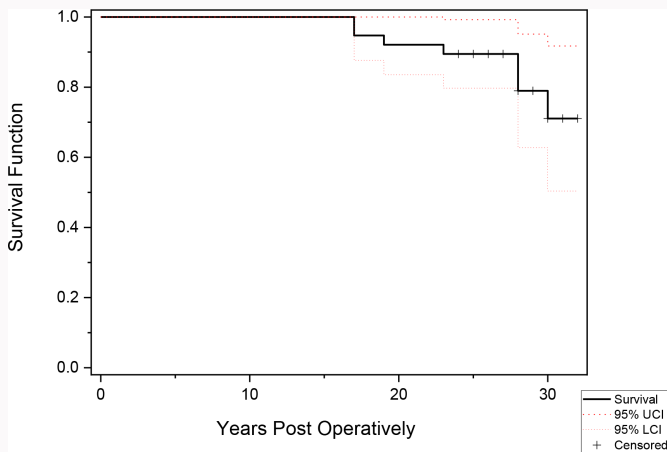


Fig. 4

Kaplan-Meier survival curve for the femoral stem. CI, confidence interval.

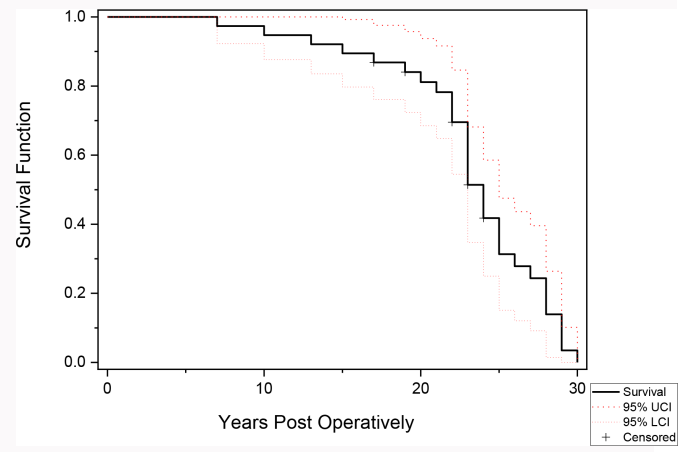


Fig. 5

Kaplan-Meier survival curve for acetabular component. CI, confidence interval.

infection, thromboembolism, dislocation, or fracture, were recorded. The radiological characteristics of the periprosthetic fractures were reviewed and are presented in [Table 1](#).

Using aseptic loosening as the endpoint, survival of the femoral component was 100% at 25 to 32 years. Revision for all causes the cumulative proportion survival of the stem was 0.97 (standard error (SE) 0.03) ([Figure 4](#)). In all, 18 hips underwent acetabular revision for aseptic loosening of these, 50% were cemented acetabular cups, and 34% were CSF. Thus, approximately 48% of the acetabular components had failed; 20-year survival of the acetabular component was 77%, but this fell to 34% at 27 years ([Figure 5](#)).

Discussion

THA is proven to be a reliable operative procedure to relieve pain and restore function, and efforts continue to minimize wear and prolong the lifespan of implants used. This plays a particularly important role in the younger patient who

subject their hips to a greater demand. Younger patients may require several revision procedures during their lifetime. With each revision, more bone stock is lost, making the procedure technically challenging, patients are exposed to a higher risk of complication, and level of function that can be restored declines.^{19–21} A concern with younger patients undergoing uncemented hip arthroplasty is the long-term effect the implant may have on the bone due to its stress shielding effect;^{22–25} long-term serial follow-up of implants provides an excellent opportunity to observe the effect of components on the bone morphology over time.

The mechanism by which the femoral component osseointegrates is similar to that observed in fracture healing. The HAC coating is substituted over time with living bone, which adheres to the titanium surface without the use of intervening fibrous tissue.^{26,27} This is demonstrated by the radiological evidence of new trabeculae being formed in the

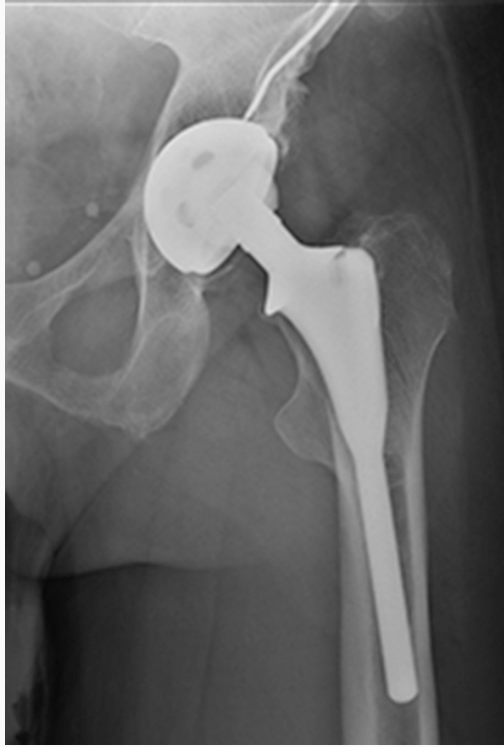

Fig. 6
Areas in the stem which are loaded, demonstrating evidence of radiological bone integration.

vicinity of the load-bearing areas of the femur. The strength of this bond is comparable to the cortical host bone itself, and this causes the whole proximal femur to function as a single unit. This is further reflected in the stems (inadvertently) implanted in varus, as 'form follows function', where the areas of bone, which are physiologically loaded with the HA stem demonstrate bone integration (even if the stem is implanted in varus), whereas cemented stems can potentially fail in the long term due to cantilever loading (Figure 6).²⁸

The patients in this series were young, high-demand individuals undergoing THA for a variety of diagnoses, with over 97% being a Dorr A- or B-type femur. The principal finding of our study, over a mean time period of 27 years (27 to 32) following surgery, is that none of the femoral components required revision for aseptic loosening. This is in spite of the fact that 18 acetabular components had undergone, or were awaiting, revision. These results are encouraging as the survival reported here is long enough to minimize the chance of patients requiring many major revision procedures during their lifetime.

The functional outcome reported in the early postoperative period persisted well into the long-term follow-up. There was a slight improvement noted across all functional scores when compared against the 17- to 25-year follow-up results. This effect is most likely due to the improvement in score in the patients who underwent acetabular revision.

Acetabular components are more prone to mechanical failure than femoral components.²⁹ In our series, the acetabulum failures in 18 hips might be attributed to the use of polyethylene sterilized in air and the use of 32 mm heads, which are known risk factors for volumetric wear.³⁰

Despite the femoral component being exposed to the same particle load, the resistance of wear products contributing to the osteolytic process can be attributed to various factors. Previous studies using HAC implants have suggested that these implants provide a barrier or create a 'sealing effect' to the ingress of wear particles into the bone-implant interface. This minimizes the chance of distal femoral osteolysis by minimizing wear beyond the metaphysis, even when the component is exposed to extensive cyclical loading over such a long time period. This may play an important factor in 'protecting' the femoral stem from aseptic loosening when compared to cemented stems, as demonstrated in the Swedish registry.³¹

From the radiographs reviewed in our study, the only evidence of radiolucencies in the femur were limited to zones 1 and 7. The radiolucent lines in zone 1 were mainly present in the proximal half of this zone, which is most likely secondary to stress shielding. Similar radiolucent lines have been noted in other HAC stems.³² No further involvement of other zones was noted when compared to our previous report.

Uncemented femoral stems have been associated with greater number of periprosthetic fractures.^{33,34} An increase in the CFR over time is associated with stress shielding, which is a risk factor for periprosthetic fracture, notably if the increase is present postoperatively.³⁵⁻³⁸ Reviewing the four periprosthetic fractures in our series, we did observe a progressive increase in the CFR over time, most likely indicating stress shielding. This may have been a contributing factor to the fractures when the patients fell – the fracture patterns observed were spiral fractures at the metaphyseal-diaphyseal junction. However, we did not observe a statistically significant change with the CFR over time in the radiographs, and there was no demonstrable bone loss or reabsorption at the proximal or other parts of the femur radiologically in the patients who did not suffer fractures.

Aside from one revision for periprosthetic fracture, all revisions were limited to the acetabulum, which is a substantially less invasive undertaking compared with revisions in which the femoral component needs to be extracted and the femur reconstructed.

In this series, there was no evidence of the crack microfracture phenomenon around any femoral component.³⁹ Anterior thigh pain has been described with other femoral components with an incidence of up to 22%,⁴⁰ it is thought to be due to movement of the femoral component. At this review, in the one patient who reported anterior thigh pain, radiographs showed the femoral component to be well fixed. This shows an initial excellent press-fit provided by the stem and subsequent excellent HA osseointegration. Other factors contributing to this could be the modulus of elasticity of titanium or abnormal bone morphology and anatomy.

Weaknesses of our study include the variation in the type of acetabular components used, with differences in head size and bearing surfaces, which may have led to differences in the rate and pattern of polyethylene wear. Additionally, there is a lack of preoperative activity-level scoring. In this review, two patients were lost to follow-up and two refused to attend clinics for functional scoring. This reflects a 10% loss to follow-up, which is much lower than anticipated at 30 years.⁴¹ Every effort was made to trace and contact patients; when they were unable to attend clinic in person, we were able

to obtain information on our primary outcome by phone or email. We did note a statistically significant increase across the CFR in the periprosthetic fracture group, although our patient sample size was small.

We conclude that at a maximum follow-up of 32 years, the Furlong HAC-coated femoral component continues to give excellent survival and functional results in young active patients. There is a risk of periprosthetic fracture, which may be caused by stress shielding.

Social media

Follow P. K. Upadhyay on X @P14USH

References

1. Levy RN, Levy CM, Snyder J, Digiovanni J. Outcome and long-term results following total hip replacement in elderly patients. *Clin Orthop Relat Res.* 1995;316:25–30.
2. Ben-Shlomo Y, Blom A, Boulton C, et al. The National Joint Registry 18th Annual Report 2021. National Joint Registry. 2021. <https://reports.njrcentre.org.uk/2020> (date last accessed 14 March 2024).
3. Singh S, Trikha SP, Edge AJ. Hydroxyapatite ceramic-coated femoral stems in young patients. A prospective ten-year study. *J Bone Joint Surg Br.* 2004;86-B(8):1118–1123.
4. Shah NN, Edge AJ, Clark DW. Hydroxyapatite-ceramic-coated femoral components in young patients followed-up for 16 to 19 years: an update of a previous report. *J Bone Joint Surg Br.* 2009;91-B(7):865–869.
5. Syed MA, Hutt NJ, Shah N, Edge AJ. Hydroxyapatite ceramic-coated femoral components in young patients followed up for 17 to 25 years: an update of a previous report. *Bone Joint J.* 2015;97-B(6):749–754.
6. Harris WH. Traumatic arthritis of the hip after dislocation and acetabular fractures: treatment by mold arthroplasty. An end-result study using a new method of result evaluation. *J Bone Joint Surg Am.* 1969;51-A(4):737–755.
7. Dawson J, Fitzpatrick R, Carr A, Murray D. Questionnaire on the perceptions of patients about total hip replacement. *J Bone Joint Surg Br.* 1996;78-B(2):185–190.
8. Murray DW, Fitzpatrick R, Rogers K, et al. The use of the Oxford hip and knee scores. *J Bone Joint Surg Br.* 2007;89-B(8):1010–1014.
9. Amstutz HC, Thomas BJ, Jinnah R, Kim W, Grogan T, Yale C. Treatment of primary osteoarthritis of the hip. A comparison of total joint and surface replacement arthroplasty. *J Bone Joint Surg Am.* 1984;66-A(2):228–241.
10. Dorr LD, Faugere MC, Mackel AM, Gruen TA, Bogner B, Malluche HH. Structural and cellular assessment of bone quality of proximal femur. *Bone.* 1993;14(3):231–242.
11. Engh CA, Massin P, Suthers KE. Roentgenographic assessment of the biologic fixation of porous-surfaced femoral components. *Clin Orthop Relat Res.* 1990;257:107–128.
12. Gruen TA, McNeice GM, Amstutz HC. "Modes of failure" of cemented stem-type femoral components: a radiographic analysis of loosening. *Clin Orthop Relat Res.* 1979;141:17–27.
13. Goetz DD, Smith EJ, Harris WH. The prevalence of femoral osteolysis associated with components inserted with or without cement in total hip replacements. A retrospective matched-pair series. *J Bone Joint Surg Am.* 1994;76-A(8):1121–1129.
14. DeLee JG, Charnley J. Radiological demarcation of cemented sockets in total hip replacement. *Clin Orthop Relat Res.* 1976;121:20–32.
15. Brooker AF, Bowerman JW, Robinson RA, Riley LH. Ectopic ossification following total hip replacement. Incidence and a method of classification. *J Bone Joint Surg Am.* 1973;55-A(8):1629–1632.
16. Kaplan EL, Meier P. Nonparametric estimation from incomplete observations. *Journal of the American Statistical Association.* 1958;53(282):457–481.
17. Cicchetti DV. Guidelines, criteria, and rules of thumb for evaluating normed and standardized assessment instruments in psychology. *Psychol Assess.* 1994;6(4):284–290.
18. Landis JR, Koch GG. The measurement of observer agreement for categorical data. *Biometrics.* 1977;33(1):159–174.
19. Brown JM, Mistry JB, Cherian JJ, et al. Femoral component revision of total hip arthroplasty. *Orthopedics.* 2016;39(6):e1129–e1139.
20. Sulco PK, Abdel MP, Lewallen DG. Management of femoral bone loss in revision total hip arthroplasty. *Hip Int.* 2015;25(4):380–387.
21. Sheth NP, Melnic CM, Rozell JC, Paprosky WG. Management of severe femoral bone loss in revision total hip arthroplasty. *Orthop Clin North Am.* 2015;46(3):329–342.
22. Harris WH. Will stress shielding limit the longevity of cemented femoral components of total hip replacement? *Clin Orthop Relat Res.* 1992;274(274):120–123.
23. Piao C, Wu D, Luo M, Ma H. Stress shielding effects of two prosthetic groups after total hip joint simulation replacement. *J Orthop Surg Res.* 2014;9:71.
24. Sanki T, Endo H, Tetsunaga T, Furumatsu T, Yamada K, Ozaki T. Ten-year outcomes of total hip arthroplasty using fit-and-fill type cementless collared straight stem implants: relationship between the initial contact status and stress shielding. *Acta Med Okayama.* 2020;74(1):7–15.
25. Sumner DR. Long-term implant fixation and stress-shielding in total hip replacement. *J Biomech.* 2015;48(5):797–800.
26. Karabatsos B, Myerthall SL, Fornasier VL, Binnington A, Maistrelli GL. Osseointegration of hydroxyapatite porous-coated femoral implants in a canine model. *Clin Orthop Relat Res.* 2001;392:442–449.
27. Landor I, Vavrik P, Sosna A, Jahoda D, Hahn H, Daniel M. Hydroxyapatite porous coating and the osteointegration of the total hip replacement. *Arch Orthop Trauma Surg.* 2007;127(2):81–89.
28. de Beer J, McKenzie S, Hubmann M, Petruccelli D, Winemaker M. Influence of cementless femoral stems inserted in varus on functional outcome in primary total hip arthroplasty. *Can J Surg.* 2006;49(6):407–411.
29. Sharma DK, Brooks S. Long-term follow-up (11 years plus) results of JRI (Furlong) total hip arthroplasty in young patients: cause for concern regarding acetabular cup? *Int Orthop.* 2006;30(5):375–380.
30. Davis ET, Pagkalos J, Kopjar B. Polyethylene manufacturing characteristics have a major effect on the risk of revision surgery in cementless and hybrid total hip arthroplasties. *Bone Joint J.* 2020;102-B(1):90–101.
31. Wyatt M, Hooper G, Frampton C, Rothwell A. Survival outcomes of cemented compared to uncemented stems in primary total hip replacement. *World J Orthop.* 2014;5(5):591–596.
32. Magill P, Hill J, O'Brien S, Stevenson M, Machenaud A, Beverland D. Observed effect of femoral component undersizing and a collarless design in the development of radiolucent lines in cementless total hip arthroplasty. *Arthroplast Today.* 2020;6(1):99–103.
33. Konow T, Baetz J, Melsheimer O, Grimberg A, Morlock M. Factors influencing periprosthetic femoral fracture risk. *Bone Joint J.* 2021;103-B(4):650–658.
34. Sershon RA, McDonald JF, Ho H, Hamilton WG. Periprosthetic femur fracture risk: influenced by stem choice, not surgical approach. *J Arthroplasty.* 2021;36(7S):S363–S366.
35. Li M, Zeng Y, Wu Y, Liu Y, Wu L, Shen B. Cementless femoral stems with lower canal fill ratio have similar mid-term to long-term outcomes to those with adequate fill ratio in Dorr type C femurs. *Arch Orthop Trauma Surg.* 2022;142(6):1265–1273.
36. Zhen P, Liu J, Li X, Lu H, Zhou S. Primary total hip arthroplasty using an uncemented Wagner SL stem in elderly patients with Dorr type C femoral bone. *J Orthop Surg Res.* 2019;14(1):377.
37. D'Ambrosio A, Peduzzi L, Roche O, Bothorel H, Saffarini M, Bonnomet F. Influence of femoral morphology and canal fill ratio on early radiological and clinical outcomes of uncemented total hip arthroplasty using a fully coated stem. *Bone Joint Res.* 2020;9(4):182–191.
38. Yeung Y, Chiu KY, Yau WP, Tang WM, Cheung WY, Ng TP. Assessment of the proximal femoral morphology using plain radiograph-can it predict the bone quality? *J Arthroplasty.* 2006;21(4):508–513.
39. Boyce TM, Fyhrie DP, Glotkowski MC, Radin EL, Schaffler MB. Damage type and strain mode associations in human compact bone bending fatigue. *J Orthop Res.* 1998;16(3):322–329.
40. Chung H, Chung SH. Correlation between anterior thigh pain and morphometric mismatch of femoral stem. *Yeungnam Univ J Med.* 2020;37(1):40–46.
41. Murray DW, Britton AR, Bulstrode CJ. Loss to follow-up matters. *J Bone Joint Surg Br.* 1997;79-B(2):254–257.

Author information

P. K. Upadhyay, MBBS, FEBOT, FRCS, PhD, Locum Consultant Orthopaedic Surgeon, Hon Professor of Engineering, Cumberland Infirmary, North Cumbria Integrated Care NHS Foundation Trust, Carlisle, UK;
School of Engineering University of Warwick, Coventry, UK.

V. Kumar, MS, FRCS (Tr&Orth), Consultant Orthopaedic Surgeon, Manchester University NHS Foundation Trust (MFT), Manchester, UK.

S. B. Mirza, MBBS, FRCS (Tr&Orth), Substantive Consultant, Trauma and Orthopaedics, University Hospital Wales, Cardiff, UK.

N. Shah, MSc, MCh (Orth), FRCS (Tr&Orth), Consultant Orthopaedic Surgeon, University Hospitals Sussex NHS Foundation Trust, West Sussex, UK.

Author contributions

P. K. Upadhyay: Formal analysis, Project administration, Writing – original draft.

V. Kumar: Formal analysis, Writing – review & editing.

S. B. Mirza: Investigation, Writing – review & editing.

N. Shah: Supervision, Writing – review & editing.

Funding statement

The authors received no financial or material support for the research, authorship, and/or publication of this article.

ICMJE COI statement

The authors have no COI disclosures to declare.

Data sharing

The data that support the findings for this study are available to other researchers from the corresponding author upon reasonable request.

Acknowledgements

The authors would like to thank Mr A. J. Edge, who instigated this study.

Open access funding

The authors report that received open access funding for this manuscript was self-funded via University Hospitals Sussex NHS Foundation Trust, UK.

© 2024 Upadhyay et al. This is an open-access article distributed under the terms of the Creative Commons Attribution Non-Commercial No Derivatives (CC BY-NC-ND 4.0) licence, which permits the copying and redistribution of the work only, and provided the original author and source are credited. See <https://creativecommons.org/licenses/by-nc-nd/4.0/>